

## Efficacy and Safety of Regenerative Treatment in Knee Osteoarthritis Patients after COVID-19 Vaccination

Pooja Pithadia<sup>1\*</sup>, Sharmila Tulpule<sup>2</sup>, Masud Ur Rehman<sup>3</sup>, Elmuntasir Mahmoud<sup>4</sup> and Mrinalini Singh<sup>5</sup>

<sup>1</sup>Biochemist, MSc Medical Biotechnology, Affiliated- Medica Pain Management Clinic, London, UK

<sup>2</sup>Orthopaedic surgeon and regenerative medicine specialist M.S. (Ortho), M.Ch. (Ortho), DABRM (U.S.) Medica Stem Cells Clinic, Dubai, UAE

<sup>3</sup>Consultant Orthopaedic Surgeon MBBS FRCS FABRAAM Medica Pain Management Clinic, Dublin, Ireland

<sup>4</sup>Consultant Ortho FRCSI, Mch Orth Medica Stem Cells Clinic, Dublin, Ireland

<sup>5</sup>Medica Stem Cells Clinic, London, UK

**\*Corresponding author:** Pooja Pithadia, Biochemist, MSc Medical Biotechnology, Affiliated- Medica Pain Management Clinic, London, UK

**Citation:** Pithadia P, Tulpule S, Rehman MU, Mahmoud E, Singh M. (2022) Efficacy and Safety of Regenerative Treatment in Knee Osteoarthritis Patients after COVID-19 Vaccination. J Stem Cell Res. 3(3):1-10.

**Copyright** © 2022 by Pithadia P. All rights reserved. This is an open access article distributed under the terms of the Creative Commons Attribution License, which permits unrestricted use, distribution, and reproduction in any medium, provided the original author and source are credited.

**Received:** July 04, 2022 | **Published:** July 28, 2022

### Abstract

**Background:** COVID-19 disease has gained much attention across the globe due to its quick transmission with a high mortality rate. Although research studies are ongoing to determine the best treatment, vaccination turned out to be the most promising preventive measure against SARS-CoV- 2. Currently, four COVID-19 vaccines are approved and used across the world. However, people undergoing regenerative treatment were doubtful whether it worked after the vaccination. In this study, we assessed the safety of the regenerative treatment in patients with knee osteoarthritis (KOA) post-COVID-19 vaccination.

**Methods:** 131 knee joints of patients aged between 45 to 85 years with KOA, grade 3-4 of the Kellgren–Lawrence scale, who received vaccination against COVID-19, were randomly administered with BMAC, Lipogem, PRP, and GOLDIC treatments. For 12 months, these patients were evaluated for side effects.

**Results:** During 12 months of follow-up, 90% of the patients experienced no side effects. Only 7% reported minor side effects like headache and sore arms to post COVID-19 vaccination.

**Conclusion:** Regenerative treatment was safe in patients with moderate-to-severe KOA for 12 months post-COVID-19 vaccination.

### **Keywords**

Bone marrow aspirate concentrate; Regenerative treatment; Knee osteoarthritis; COVID-19; COVID-19 vaccination; Safety

## **Introduction**

Although the SARS-CoV-2 disease originated in China, it has globally affected lives and livelihoods, followed by widespread social, economic, and psychological issues. The increase in disease transmission, asymptomatic carriers, and arousal of novel variants led to acute respiratory distress syndrome (ARDS), multiple organ failure, and high mortality rates across the globe [1].

Research works are ongoing to determine the best treatment against COVID-19. However, vaccination proves to be the most promising solution to combat the global COVID-19 pandemic [1].

The discovery and development of COVID-19 vaccines were rapid and successful, with few manufacturers obtaining market authorization for their vaccines in the first year. Currently, they are used across the globe for mass immunization programs [2].

The four approved vaccines developed against the COVID-19 virus include Pfizer, Moderna, Astra-Zeneca Oxford, and Janssen Johnson & Johnson. Pfizer, Moderna, and Astra-Zeneca Oxford involve two doses at 21 days, 28 days, & 12 weeks apart, respectively. Janssen Johnson & Johnson involves only one dose. These vaccines' side effects may be rare allergies, anaphylaxis, blood clots, and thrombocytopenia [3]. The worldwide vaccine efficacy data justifies that vaccination can significantly prevent mortality rates [2].

Still, a few incomplete questions were left answered regarding the duration of immunity, prevention of COVID-19 transmission, and protection against emerging novel variants.<sup>2</sup> Moreover, people undergoing or planning to undergo regenerative treatment were doubtful whether it works after the COVID-19 vaccination without any side effects.

There is no clinical study on the effect of regenerative treatment post-COVID-19 vaccination. Hence, the major objective of this study was to assess the safety of regenerative treatment in patients with knee osteoarthritis (KOA) post-COVID-19 vaccination.

## Materials and Methods

### Study Design

The current research work was a prospective interventional study that involved an administration of regenerative treatment (BMAC, Lipogems, PRP, GOLDIC) among patients with osteoarthritic knees who received double doses of COVID-19 vaccination. The COVID-19 vaccines were found to be Pfizer, Moderna, Astra-Zeneca Oxford, the combinational vaccination of Pfizer and Astra-Zeneca Oxford, and Janssen Johnson & Johnson.

These patients were followed up for one year between April 2021 and May 2022 to determine the safety of regenerative treatment post-COVID-19 vaccination by monitoring any adverse events.

For this study, the researchers selected the participants from patients with knee pain referred to the Medica Pain Management clinic in the UK, Ireland and Dubai between December 2020 and August 2021.

Every patient who had already received double doses of COVID-19 vaccination had a direct consultation where regenerative treatment methods and side effects were explained in detail before participating in the study. Finally, all patients gave informed consent forms before any treatment procedures were performed. All complications were carefully followed.

### Study Inclusion/Exclusion Criteria

The inclusion criteria of this study were males and females, aged 45 to 85 years, grades 3 and 4 (moderate to severe) of the Kellgren–Lawrence scale in X-ray/MRI scan within the past three months, with a symptom duration of more than six months, Visual Analogue Scale of more than three, absence of any pathologic conditions around the knee such as bursitis or cellulitis, having previously tried a regimen of systemic anti-inflammatory medicines or physical therapy and injections (corticosteroids or viscosupplements), have already received double doses of COVID-19 vaccines, and willingness to participate in the study.

Exclusion criteria include any patient parameters falling outside of the inclusion criteria parameters, not receiving one or both doses of COVID-19 vaccines, NSAIDs use, hyaluronic acid-based injection to the affected osteoarthritic joint within the past six months, or any corticosteroid injection to the affected knee joint within the previous three months, any current oral or parenteral steroid, blood thinners, a history of cancer, genetic disorder, pregnancy or breastfeeding; history of knee arthroplasty or other surgeries; the presence of peripheral neuropathy, active radiculopathy, or myopathy in lower limbs; BMI > 42; severe gastrointestinal, hepatic, respiratory, cerebral, renal, and cardiovascular diseases; any severe local infection; any condition with bleeding tendency; inability to finish the given questionnaires before the trial were excluded.

## Sample preparation

### BMAC

Bone marrow was processed using a multiport bone marrow aspiration needle derived from the posterior superior iliac crest. The total quantity of bone marrow harvested was 60 cc for one knee and 100-120 cc for both knees treatment. The manufacturer's preparation and processing protocol were used, and bone marrow aspirate concentrate (BMAC) was prepared using the Arthrex Angel centrifugation system. (Arthrex, Inc. <https://www.arthrex.com/orthobiologics/arthrex-angel-system>) The final quantity of BMAC derived varied from 5 ccs to 7 cc per affected knee joint.

### Platelet-rich plasma (PRP)

Autologous PRP was prepared with a double spin method. Autologous blood (25.5 mL) was extracted from the patient via venipuncture and collected in 3×8.5mL BD Vacutainers (BD, Franklin Lakes, New Jersey, USA) consisting of ACD (trisodium citrate 22.0g/L, citric acid 8.0g/L, and dextrose 24.5g/L) to halt clotting. Using a benchtop centrifuge, the collected blood underwent an initial spin at 1000rpm for 10 minutes to derive multilayered components such as a platelet-poor plasma (PPP) level and a middle buffy coat level (rich in platelets and leucocytes), as well as a red blood cell layer [4].

Platelet-poor plasma (PPP) was extracted to the red blood cell layer level. It was then placed in a sterile vacutainer and underwent a second hard spin at 3500rpm for 5 minutes. After spinning, it results in the development of PPP and a platelet plug. PPP was then extracted to the level of 10mm and discarded. The PPP and a residual platelet plug were reconstituted with a mild manual agitation, which resulted in the development of 3mL leukocyte-rich PRP [4].

### Lipogem

In the MFAT sample preparation protocol, a small incision was made using a #11 scalpel after anaesthetizing the superficial skin using 5–10 cc of 1% lidocaine. A blunt tip anaesthesia cannula was used with a 60-cc syringe to infiltrate 120 ccs of tumescent anaesthesia to the lower part of the abdomen. The cannula was directed towards the umbilicus and posteriorly toward the flank through the same incision site. After placing the lipoaspirate cannula through the incision site, 30 ccs of lipoaspirate was obtained through a low-pressure vacuum. Approximately 30 cc of lipoaspirate collected in a syringe was transferred to a sterile cup to decant. After eliminating the tumescent anaesthesia, care was taken to prevent air entry into the graft. The collected lipoaspirate was then transferred to the Lipogems manual processing device for washing and mechanical breakdown purposes. The final product was collected in 3-cc syringes for the injection treatment under ultrasound guidance to ensure proper placement. The overall procedure took 60 minutes the completion, including the harvesting and creation of MFAT [5].

### GOLDIC Therapy

The GOLDIC® procedure sample preparation protocol was as follows: four x 10 mL of blood was extracted from each patient using four GOLDIC® BTS syringes (ArthroGen GmbH, Ringsee, Germany) initially. All four syringes were incubated at 37°C for 24 hours. The incubation must be less than 28 hours

**Research Article** | Pithadia P, et al. J Stem Cell Res. 2022, 3(3)-38.

**DOI:** [https://doi.org/10.52793/JSCR.2021.3\(3\)-38](https://doi.org/10.52793/JSCR.2021.3(3)-38)

to avoid the likelihood of red blood cell lysis. They may not be desirable as this additional incubation might negatively change the serum injectate's characteristics. There was no requirement to add an anti-clotting agent, as even if clot forms, it may not impact cellular separation and the formation of activated serum. After the incubation, all four tubes were centrifuged at 4000 rpm (2250 g) for nearly 10 minutes. Once the centrifugation was completed, the conditioned serum supernatant was collected and filtered through a 0.22  $\mu$ M syringe tip filter (Millex GP, Merck Millipore, Tullagreen, Carrigtwohill, Cork, Ireland). The product was then used for immediate IA injection or stored at  $-20^{\circ}\text{C}$  for later utilization up to eight weeks from processing [6].

### Intervention

All patients confirmed the cessation of NSAIDs at least five days before the procedure. Before injecting the final products, the affected knee joint site was cleansed using betadine/chloroprene. Next, the target region was infiltrated with a dilute solution of .00125% lidocaine, giving an anaesthetic effect on local soft tissues. In the next step, the patients were randomly allocated into BMAC, Lipogems, PRP, and GOLDIC treatment groups and were administered with respective treatments under ultrasound guidance. The patients were also instructed to avoid oral NSAIDs for four to six weeks after the procedure. They were also advised to avoid high-impact activity for two weeks.

### Outcomes

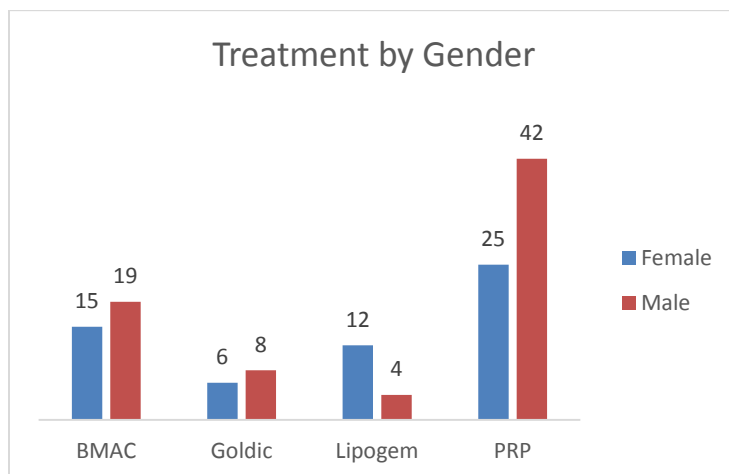
All patients were evaluated up to 12 months after regenerative treatment for the occurrence of any adverse events such as pain, headache, sore arms, allergy, infection, stiffness, itching, nausea/vomiting, dizziness, bleeding, blood clots, temporary increase in blood sugar level, blood pressure level and nerve injury.

### Results

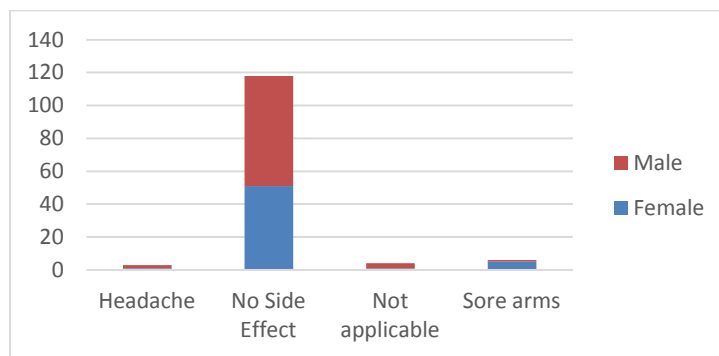
We assessed 138 patients with knee osteoarthritis pain who were the candidates to participate in our study. 7 patients had one exclusion criterion, i.e., they were not received COVID-19 vaccination, and so they were not included. The remaining patients ( $n = 131$ ) were randomly administrated with regenerative treatment (BMAC, Lipogems, PRP, GOLDIC) post-COVID-19 vaccination in multiple locations of Medica Pain Management Clinic.

The mean age was 60 years, ranging from 19 to 85 years, and there were 73 (56%) males and 58 (44%) females. The degree of the degenerative arthritis was evaluated as grade III-IV by K-L grade (Kellgren–Lawrence grading scale) on the standing anteroposterior (AP) view. 62 knees were evaluated to be K–L grade III, and 69 were evaluated to be K–L grade IV, respectively.

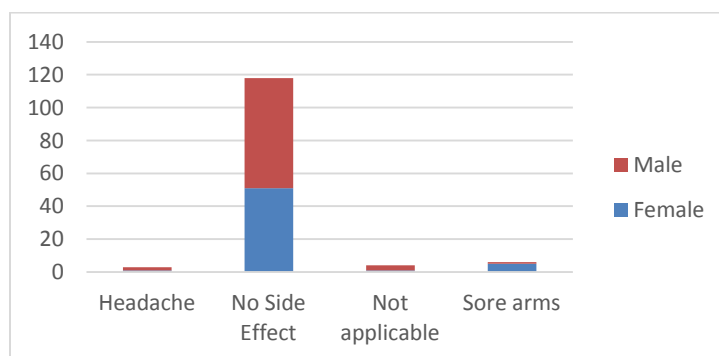
Among regenerative treatment types, PRP therapy was performed on more participants, as shown in Figure 1. After 12 months of follow-up, as highlighted in Figures 2 and 3, 90% of patients experienced no side effects with all regenerative treatments even after receiving COVID-19 vaccination. Only 7% of the patients experienced minor side effects like headache and sore arms after undergoing PRP treatment post-vaccination. Males experienced more headaches while females experienced sore arms as a side effect.



**Figure 1:** Regenerative Treatment by Gender.



**Figure 2:** Side effects by Gender.



**Figure 3:** Regenerative Treatment by Side effects.

## Discussion

This research aimed to study the safety of BMAC, Lipogem, PRP, or GOLDIC injections as standalone treatments for knee OA post-approved COVID-19 vaccination. This study revealed no significant side effects for all BMAC, Lipogem, PRP, and GOLDIC groups 12 months after the injection. Moreover, this preliminary clinical study showed that few patients reported minor headaches and sore hands.

An administration of COVID-19 vaccination dose on elders aged 60 years or more, after 5 months since the completion of the vaccination cycle, reduced the incidence of COVID-19 and severe illness [7].

Even after vaccination, all patients should follow public health measures such as wearing a face mask, physical distancing, regular hand washing, COVID-19 testing, and isolation as required [8].

It was prevalent to experience symptoms like fatigue, mild fever, soreness, or headache within 48 hours after vaccination. If the patient experiences these symptoms for more than 48 hours, it is recommended to inform the physician immediately. If required, the patient can avoid scheduling regenerative treatment if vaccine complications are expected.

The WHO report showed no cross interaction between COVID-19 vaccines and antibiotic treatment [9]. The same applies to the various regenerative treatment, and the patient can go ahead with the full course of treatment.

Moreover, regenerative cells have unique characteristics that can make patients resistant to viral diseases by enhancing the innate immune response at the early stage of infection [10].

The mode of action of regenerative medicine involves a series of events that occur over time. The growth factors may be secreted continuously after the injection of regenerative cells into the affected knee joint, followed by a cascade of events that leads to healing [11]. These cascade events involved an immunomodulatory effect, while the anti-inflammatory effect may be associated with the soluble growth factors produced by the mesenchymal stem cells [12,13].

The BMAC has the potential to culture or differentiate while secreting a higher volume of beneficial chemokines [14]. Thus, higher cellular components grown in culture were reported to have the maximum potential for tissue regeneration and anti-inflammatory effects.

PRP also consists of proteins that could modify the pain receptors, thereby reducing pain sensation with its anti-inflammatory effect on affected tendons [4,16].

In addition, MFAT was also rich in anti-inflammatory, angiogenic, immunomodulatory growth factors, and cytokines such as IL1-RA, PDGF, placental growth factor, dipeptidyl peptidase 4, matrix metalloproteinase (MMP) -7, MMP-9, Ang-1, Ang-2, adiponectin, and HGF [5,7,18]. MFAT exhibits further anti-inflammatory properties by blocking monocyte inflammatory functions [5,17].

Furthermore, the GOLDIC procedure has shown upregulation of granulocyte-colony stimulation factor (G-CSF) and plasma gelsolin (pGSN), which both play a crucial role in tissue regeneration [6,19-22]. GOLDIC® may modulate the cytokine level, leading to an improvement in the clinical outcome [6].

Conditioned autologous serum (CAS) like GOLDIC® also produces anti-inflammatory cytokines such as interleukin-1 receptor antagonist (IL-1ra) that inhibit intra-articular destructive effects of interleukin -1 (IL-1) [23,24].

Generally, regenerative treatments such as BMAC, Lipogem, PRP, or GOLDIC were considered relatively simple procedures that could be efficiently completed in an outpatient setting.

Nonetheless, International Health Ministries like CDC, Public health England, WHO and the vaccine manufacturers have not issued any warning for patients undergoing regenerative treatment after the COVID-19 vaccination. The Indian Health Ministry has reported that the recipients of regenerative treatment can take COVID-19 vaccination as there has been no evidence of side effects.

To our knowledge, this was the first direct study on the safety aspect of regenerative treatment after COVID-19 vaccination. Currently, this study is in progress to clarify some of the commonly asked questions regarding the efficacy and lasting durability of these procedures, especially after approved vaccination. In this study, only the preliminary data was revealed recommending the safety of a cost-effective outpatient procedure of BMAC, Lipogem, PRP, or GOLDIC injections in the knee.

### **Study limitations**

The limitations of the present study include the lack of follow-up only for a shorter duration, objective assessment of the interventional outcomes, and lack of a control group due to the minimal sample size. The patients realized there was no control group; hence, their survey responses might have been biased. There was no comparison of the outcomes of every regenerative treatment method for various KL grades and varied COVID-19 vaccination groups. To date, there has been a lack of high-quality research studies on regenerative treatment for more than two years with various trial settings for knee osteoarthritis treatment.

### **Future investigations**

The duration of follow-up of the current study was only one year. However, the current cohort study could be continued for the second and third years, thereby reporting the efficacy of regenerative treatment post-COVID-19 vaccination in the following research paper.

### **Conclusion**

This study demonstrated that regenerative treatment such as BMAC, Lipogem, PRP, and GOLDIC procedures was safe in patients with moderate to severe knee arthritis for up to 12 months. Hence, people undergoing or planning to undergo regenerative treatment can proceed with the treatment even after the COVID-19 vaccination as there are no significant side effects.



The results of the current study were established based on subjective findings. Further detailed research should be conducted to assess their effect with different methods, long-term follow-up, and objective findings.

## Declarations

### Consent for publication

Not applicable.

## Competing Interests

The authors declare that they have no competing interests.

## References

1. Teijaro JR, Farber DL. (2021) COVID-19 vaccines: modes of immune activation and future challenges. *Nat Rev Immunol.* 21:195–97.
2. Heinz FX, Stiasny K. (2021) Distinguishing features of current COVID-19 vaccines: Knowns and unknowns of antigen presentation and modes of action. *NPJ Vaccines.* 6:104.
3. Mascellino MT, Di Timoteo F, De Angelis M, Oliva A. (2021) Overview of the Main Anti-SARS-CoV-2 Vaccines: Mechanism of Action, Efficacy and Safety. *Infect Drug Resist.* 14:3459-76.
4. Pithadia P, Surya P, Tulpule S. (2021) Effect of platelet-rich plasma therapy in conjunction with physical therapy for rotator cuff Tendinopathy. *Int. J. Clin. Rheumatol.* 16(7):216-20.
5. Mautner K, Bowers R, Easley K, Fausel Z, Robinson R. (2019) Functional Outcomes Following Microfragmented Adipose Tissue Versus Bone Marrow Aspirate Concentrate Injections for Symptomatic Knee Osteoarthritis. *Stem Cells Transl Med.* 8(11):1149-56.
6. Schneider U, Kumar A, Murrell W, Ezekwesili A, Yurdi NA, et al. (2021) Intra-articular gold induced cytokine (GOLDIC®) injection therapy in patients with osteoarthritis of knee joint: a clinical study. *Int Orthop.* 45(2):497-7.
7. Bar-On, Yinon & Goldberg, Yair & Mandel, et al. (2021). Protection of BNT162b2 Vaccine Booster against Covid-19 in Israel. *N Engl J Med.* 385:1393-1400.
8. [https://www.health.qld.gov.au/data/assets/pdf\\_file/0024/1035249/covid-19-vaccine-cancer.pdf](https://www.health.qld.gov.au/data/assets/pdf_file/0024/1035249/covid-19-vaccine-cancer.pdf)
9. [https://www.who.int/news-room/questions-and-answers/item/coronavirus-disease-\(covid-19\)-vaccines](https://www.who.int/news-room/questions-and-answers/item/coronavirus-disease-(covid-19)-vaccines)
10. Afarid M, Sanie-Jahromi F. (2021) Mesenchymal Stem Cells and COVID-19: Cure, Prevention, and Vaccination. *Stem Cells International.*
11. Noth U, Ander F, Steinert I. (2008) Technology insight: adult mesenchymal stem cells for osteoarthritis therapy. *Nat Clin Pract Rheumatol.* 4(7):371–80
12. Iijima H, Isho T, Kuroki H, Takahashi M, Aoyama T. (2018) Effectiveness of mesenchymal stem cells for treating patients with knee osteoarthritis: a meta-analysis toward the establishment of effective regenerative rehabilitation. *NPJ Regen Med.* 3:15.
13. Bansal H, Comella K, Leon J, Verma P, Agarwal D, et al. (2017) Intra-articular injection in the knee of adipose derived stromal cells (stromal vascular fraction) and platelet rich plasma for osteoarthritis. *J Transl Med.* 15:141.
14. Cassano JM, Kennedy JG, Ross KA, Fraser EJ, Goodale MB, et al. (2018) Bone marrow concentrate, and platelet-rich plasma differ in cell distribution and interleukin 1 receptor antagonist protein concentration. *Knee Surg Sports Traumatol Arthrosc.* 26(1):333-42.

15. Hauser RA, Orlofsky A. (2013) Regenerative injection therapy with whole bone marrow aspirate for degenerative joint disease: a case series. *Clin Med Insights Arthritis MusculoskeletDisord*. 6:65-72
16. Zhang J, Wang JH. (2014) PRP treatment effects on degenerative tendinopathy – an in vitro model study. *Muscles. Ligaments. Tendons. J*. 4:10–7.
17. Ceserani V, Ferri A, Berenzi A, Benetti A, Ciusani E, et al. (2016) Angiogenic and anti-inflammatory properties of micro-fragmented fat tissue and its derived mesenchymal stromal cells. *Vasc Cell*. 8:3.
18. Vezzani B, Shaw I, Lesme H, Yong L, Khan N, et al. (2018) Higher pericyte content and secretory activity of microfragmented human adipose tissue compared to enzymatically derived stromal vascular fraction. *Stem Cells Translational Medicine*. 7(12):876–86.
19. Suhler E, Lin W, Yin HL, Lee WM. (1997) Decreased plasma gelsolin concentrations in acute liver failure, myocardial infarction, septic shock, and myonecrosis. *Crit Care Med* 25(4):594-8.
20. Li GH, Arora PD, Chen Y, McCulloch AC, Liu P. (2012) Multifunctional roles of gelsolin in health and disease. *Medicinal Research Reviews* 32(5):999-1025.
21. Okano T, Mera H, Itokazu M, Okabe T, Koike T, et al. (2014) Systemic administration of granulocyte colony stimulating factor for osteochondral defect repair in a rat experimental model. *Cartilage* 5(2):107-13.
22. Piktel E, Levental I, Durnaś B, Janmey PA, Bucki R. (2018) Plasma gelsolin: Indicator of inflammation and its potential as a diagnostic tool and therapeutic target. *Int J Mol Sci*. 19(9):2516.
23. Baltzer AW, Moser C, Jansen SA, Krauspe R. (2012) Autologous conditioned serum (Orthokine) is an effective treatment for knee osteoarthritis. *Osteoarthr Cartilage* 17(2):152-60.
24. Schneider U, Wallich R, Felmet G, Murrel WD. (2017) Gold-Induced Autologous Cytokine Treatment in Achilles Tendinopathy. *Muscle and Tendon Injuries*. 411-19.